



Uploaded to VFC Website ~ October 2012 ~

This Document has been provided to you courtesy of Veterans-For-Change!

Feel free to pass to any veteran who might be able to use this information!

For thousands more files like this and hundreds of links to useful information, and hundreds of "Frequently Asked Questions, please go to:

[Veterans-For-Change](#)

*Veterans-For-Change is a 501(c)(3) Non-Profit Corporation
Tax ID #27-3820181*

If Veteran's don't help Veteran's, who will?

We appreciate all donations to continue to provide information and services to Veterans and their families.

https://www.paypal.com/cgi-bin/webscr?cmd=_s-xclick&hosted_button_id=WGT2M5UTB9A78

Note: VFC is not liable for source information in this document, it is merely provided as a courtesy to our members.

Item ID Number 01344

Author Knepshield, James H.

Corporate Author Office of the Surgeon General and Center of Military Hist

Report/Article Title Section III. Toxic Effects Following Ingestion of C-4
Plastic Explosive

Journal/Book Title Internal Medicine in Vietnam, Volume II, General Medici

Year 1982

Month/Day

Color

Number of Images 5

Description Notes

MEDICAL DEPARTMENT, UNITED STATES ARMY

INTERNAL MEDICINE IN VIETNAM

Volume II

GENERAL MEDICINE AND INFECTIOUS
DISEASES

Editors for Internal Medicine

Brigadier General ANDRE J. OGNIBENE, MC, USA, and
Colonel O'NEILL BARRETT, Jr., MC, USA (Ret.)

OFFICE OF THE SURGEON GENERAL

AND

CENTER OF MILITARY HISTORY

UNITED STATES ARMY

WASHINGTON, D.C., 1982

1950's, produced severe degrees of hemolytic anemia uncomplicated by renal failure. In view of the frequency with which this red cell enzyme deficiency has been reported throughout the world, it is surprising that renal failure has not been more common.

The deployment of large numbers of American troops to Southeast Asia exposed individuals with the enzyme deficiency to the hemolyzing agent primaquine, as well as dapsone (diaminodiphenylsulfone) in some geographic sectors. The quantity of these drugs taken for routine chemoprophylaxis (primaquine, 45 mg base once per week; dapsone, 25 mg per day) was well below the amounts that have produced clinically overt hemolysis in most G6PD-deficient black American subjects; however, this was not always true in the white soldier (Carson and Frischer 1966).

Two cases of acute renal failure in G6PD-deficient black American troops in South Vietnam were reported. Massive intravascular hemolysis in these patients was not induced by the antimalarial agents or by other drugs per se but was associated with unsuspected rickettsial infections. One patient had scrub typhus and the other, murine typhus (Whelton, Donadio, and Elisberg 1968).

A review of 3 years' experience in Vietnam with acute renal insufficiency (table 103) shows that 31 percent of admissions were for medical causes. There was an overall survival rate of 79 percent in the medical group treated during that period.

TABLE 103.—*Survival rate of patients with acute renal insufficiency of medical etiology, 629th Medical Detachment (Renal)*

Item	September 1966- September 1967	1 Aug. 1967- 31 Aug. 1968	1 Aug. 1968- 31 July 1969
Total cases referred	45	102	130
Total acute renal insufficiency of medical etiology	14	27	44
Total survivors of medically caused acute renal insufficiency	11 (79%)	18 (66%)	38 (86%)

Source: Tabulated by James H. Knepshield, M.D., and William J. Stone, M.D., formerly of the 629th Medical Detachment.

Section III. Toxic Effects Following Ingestion of C-4 Plastic Explosive

James H. Knepshield, M.D., and William J. Stone, M.D.

Composition C-4, the most common plastic explosive used by field units in Vietnam, is a mixture of four potentially toxic substances: RDX (cyclonite), 91 percent; polyisobutylene, 2.1 percent; motor oil, 1.6 percent; and di(2-ethylhexyl) sebacate, 5.3 percent. Figure 92 shows the chemical structure for the major com-

This section is taken from the following article: Stone, W. J.; Paletta, T. L.; Heiman, E. M.; Bruce, J. I.; and Knepshield, J. H. 1969. Toxic effects following ingestion of C-4 plastic explosive. *Arch. Int. Med.* 124: 726-30 (© 1969, American Medical Association).

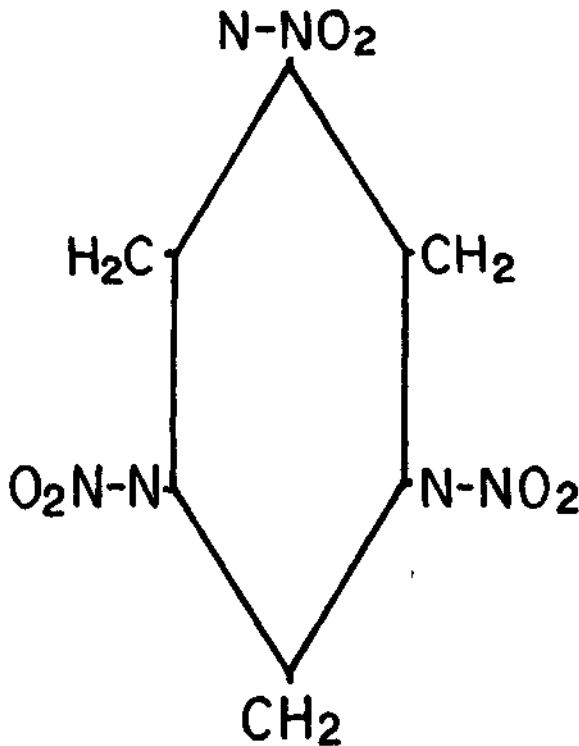


FIGURE 92.—Chemical structure of RDX (cyclotrimethylenetrinitramine, cyclonite, or Hexogen). (Stone, W. J.; Paletta, T. L.; Helman, E. M.; Bruce, J. I.; and Kneppshield, J. H. 1969. *Arch. Int. Med.* 124: 726-30. © 1969, American Medical Association.)

ponent, RDX, a colorless crystal which is highly insoluble in water (0.0076 g/100 g solvent at 25°C) (DA-TM). Because C-4 is a malleable solid, burns without explosion, and is relatively insensitive to impact or friction, it can be easily transported and stored without undue precautions (fig. 93). A blasting cap is employed as a detonator. C-4 may even be used as a field cooking fuel when other sources of heat are unavailable. However, when it is ingested or inhaled in significant quantities, by either accident or intent, a dramatic clinical picture develops within a few hours. Generalized seizures, gross hematuria, severe nausea and vomiting, muscle twitching, and mental changes occur.

It was common knowledge among the field troops in Vietnam that the ingestion of a small quantity of C-4 produces a "high" similar to that produced by alcohol. The exact frequency of ingestion of the material was not known; however, several serious intoxications from this agent were seen in every major military hospital in the Republic of Vietnam. Toxic effects of C-4 have also involved the civilian community in the United States. Inhalation of the dust was incriminated when factory workers who handled and packed the explosive experienced convulsions (Merrill 1968). C-4 is a potential health hazard in the



FIGURE 93.—Rounds of 106 mm white phosphorus are placed on top of C-4 explosive at an ammunition dump.

United States because of its availability on many military installations, although rigid control of its use makes this unlikely.

The six male patients summarized here had toxic effects from C-4 severe enough to warrant hospitalization (table 104). Their ages ranged from 20 to 35 years, with an average of 24 years. The estimated quantity of ingestion in three of the patients was 25 to 180 g (average 77 g). Data for two of the patients are from Merrill's report (1968).

TABLE 104. — *Symptoms and signs of six patients with C-4 intoxication*

Symptoms and signs	Number positive	Percent positive
Generalized seizures	6	100
Hematuria	5	83
Coma	4	67
Fever	4	67
Headaches	3	50
Lethargy	2	33
Nausea and vomiting	2	33
Oliguria	2	33

Sources: (1) Stone, W. J.; Paletta, T. L.; Heiman, E. M.; Bruce, J. I.; and Kneppshield, J. H. 1969. Toxic effects following ingestion of C-4 plastic explosive. *Arch. Int. Med.* 124: 726-30. © 1969, American Medical Association. (2) Merrill, S. L. 1968. Ingestion of an explosive material, composition C-4: A report of two cases. *USARV M. Bull.* (USARV Pam 40-8). March-April, pp. 5-11.

All patients were admitted to the hospital for the management of generalized seizures. When initially seen, most were conscious but stared into space confusedly. They were restless and unpredictable and required restraints. At frequent intervals, generalized seizures lasting 1 to 2 minutes occurred. Between seizures, the state of consciousness varied from coma to lethargy. Other prominent symptoms and signs were severe neuromuscular irritability with muscular twitching and hyperactive reflexes, myalgias, frontal headaches, nausea, vomiting, gross hematuria, and fever. Within 48 hours, the patients were able to answer simple questions and follow directions, but orientation, concentration, recall, and memory for recent and remote events were impaired. After 1 week, the sensorium cleared; however, remote memory continued to be defective with spotty recall for both personal experiences and well-known facts. Followup indicated that mental capacity had returned to normal in about 1 to 2 months. Neuromuscular irritability, gastrointestinal symptoms, hematuria, and fever abated within 48 hours. Headaches persisted for 1 to 3 weeks.

The abnormal laboratory findings are summarized in table 105. Within 2 weeks, all the abnormal values returned to normal except for the hematocrit in one patient and urinary protein excretion in another.

During the first week following ingestion of C-4, muscle, liver, and renal biopsies were performed on a patient with an elevated SGOT (serum glutamic-oxaloacetic transaminase) (354 units) and moderate azotemia with microscopic hematuria. Although the muscle biopsy was normal, muscle injury was still considered most likely because the patient complained of myalgias and muscle tenderness. Only a small portion of the latissimus dorsi was examined. The absence of hepatomegaly and of abnormal findings in the liver function studies and liver biopsy effectively excluded liver involvement. Renal biopsy showed minimal changes consisting of mild vacuolization of the proximal tubules most likely caused by mannitol therapy. There was transient hematuria and azotemia. Although a glomerulitis could also account for these abnormalities, the absence of glomerular changes by light and electron microscopy in the renal biopsy obtained 5 days after the ingestion made this diagnosis improbable. The early ad-